

21-week Routine Antenatal Ultrasound Scan

Ravi Shanker Singh, Vikrant Bardhan, K. S. Sunil Kumar, Sonal Saran*

Department of Radiodiagnosis, All India Institute of Medical Sciences, Rishikesh, Uttar Pradesh, India

SECTION 1 – QUIZ

CASE

A 24-year-old female presented to the obstetrics outpatient clinic for routine antenatal checkup at 21 weeks of gestation. This was her first pregnancy, and there was no history of previous miscarriage. Earlier, the ultrasound was done at around 10 weeks of gestation, which was normal. Her physical examination was unremarkable. An ultrasound scan was advised for the patient, which is shown in Figure 1 and Video 1.

WHAT IS YOUR INTERPRETATION?

Declaration of patient consent

The authors certify that they have obtained all appropriate patient consent forms. In the form, the patient has given her consent for her images and other clinical information to be reported in the journal. The patient understands that name and initials will not be published and due efforts will be made to conceal identity, but anonymity cannot be guaranteed.

Financial support and sponsorship

Nil.

Conflicts of interest

There are no conflicts of interest.

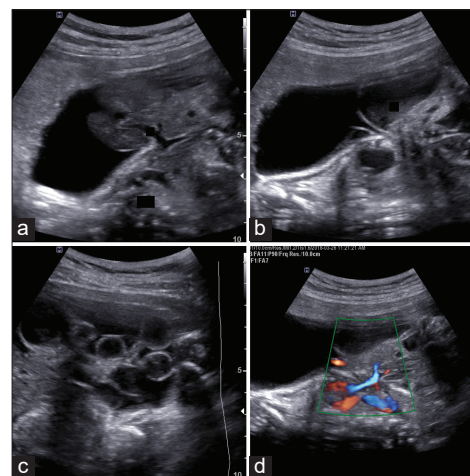


Figure 1: Antenatal ultrasound scan showing fetus with a congenital abnormality

Received: 18-02-2021 Revised: 02-03-2021 Accepted: 23-04-2021 Available Online: 21-08-2021

Video Available on: www.jmuonline.org

Access this article online

Quick Response Code:



Website:
www.jmuonline.org

DOI:
10.4103/JMU.JMU_42_21

Address for correspondence:

Dr. Sonal Saran,
Department of Radiodiagnosis, All India Institute of Medical Sciences,
Rishikesh, Uttar Pradesh, India.
E-mail: sonalsaranmalik@gmail.com

This is an open access journal, and articles are distributed under the terms of the Creative Commons Attribution-NonCommercial-ShareAlike 4.0 License, which allows others to remix, tweak, and build upon the work non-commercially, as long as appropriate credit is given and the new creations are licensed under the identical terms.

For reprints contact: WKHLRPMedknow_reprints@wolterskluwer.com

How to cite this article: Singh RS, Bardhan V, Kumar KS, Saran S. 21-week routine antenatal ultrasound scan. J Med Ultrasound 2022;30:241.